

Case Report

## A Rare Cause of Neonatal Salt Wasting Syndrome: Clinical Management of a Case Diagnosed with Pseudohypoaldosteronism Due to a Novel Homozygous Variant in the *SCNN1B* Gene

Singin B et al. Pseudohypoaldosteronism due to *SCNN1B* Variant

Berna Singin<sup>1</sup>, Zeynep Donbaloğlu<sup>1</sup>, Ebru Barsal Çetiner<sup>1</sup>, Kürşat Çetin<sup>1</sup>, Nurten Özkan Zarif<sup>2</sup>, Kıymet Çelik<sup>2</sup>, Ercan Mıhçı<sup>3</sup>, Özden Altıok Clark<sup>4</sup>, Hale Tuhun<sup>1</sup>, Mesut Parlak<sup>1</sup>

<sup>1</sup>Department of Pediatric Endocrinology, Akdeniz University Hospital, Antalya, Turkey

<sup>2</sup>Department of Neonatology, Akdeniz University Hospital, Antalya, Turkey

<sup>3</sup>Department of Pediatric Genetics, Akdeniz University Hospital, Antalya, Turkey

<sup>4</sup>Department of Medical Genetics, Akdeniz University Hospital, Antalya, Turkey

### What is already known on this topic?

Pseudohypoaldosteronism is a rare salt-wasting syndrome characterized by marked resistance to aldosterone in peripheral target tissues. Differentiating between various adrenal insufficiencies is crucial because the treatment approaches differ. Additionally, patient adherence can be challenging due to the necessity of taking large amounts of oral medications.

### What this study adds?

This article outlines our experience treating a patient with PHA caused by an *SCNN1B* variant, emphasizing the difficulties faced in clinical management. In our case, a homozygous variant c.1234dup (p.Glu412Glyfs\*39) was identified in exon 8 of the *SCNN1B* gene. This variant has not been previously reported in the literature.

### Abstract

Pseudohypoaldosteronism (PHA) is a rare disorder that, if not promptly recognized and treated, can lead to life-threatening hyperkalemia resulting in cardiac arrest and death. Systemic PHA is caused by variants that deactivate the epithelial sodium channel (ENaC) subunits. Management is challenging due to high-dose oral replacement therapy, and patients with systemic PHA require lifelong treatment. Here, we present the clinical course of a newborn diagnosed with PHA at 7 days of age due to severe dehydration, inadequate feeding, vomiting, and lethargy. The patient was found to be homozygous for the variant c.1234dup (p.Glu412Glyfs\*39) in exon 8 of the *SCNN1B* gene. The patient had multiple hospitalizations during follow-up and died at the age of 10 months due to pneumonia. Maintaining a high clinical suspicion for PHA is crucial for initiating treatment and preventing potential cardiac arrest and death in these patients. Further research is needed to determine the significance of such novel mutations in this disease.

**Keywords:** Systemic pseudohypoaldosteronism, hyponatremia, hyperkalemia, salt wasting, sodium polystyrene sulfonate, calcium polystyrene sulfonate

Mesut Parlak MD, Department of Pediatric Endocrinology, Akdeniz University Hospital, Antalya, Turkey

0000-0002-3550-1425

mesutparlak@akdeniz.edu.tr

11.10.2024

12.12.2024

Epub: 26.12.2024

### Introduction

Pseudohypoaldosteronism (PHA) is a rare salt-wasting syndrome characterized by marked resistance to aldosterone in peripheral target tissues. There are two main types of PHA: type 1 PHA and type 2 PHA. Type 1 PHA can be inherited in an autosomal dominant (AD) or autosomal recessive (AR) manner. The AD form (renal form) is associated with mutations in the mineralocorticoid receptor (MR) in principal cells of the kidney, affecting sodium transport. The AR form (systemic form), on the other hand, is linked to mutations in the epithelial sodium channel (ENaC), expressed in various organs including renal tubules, lungs, colon, sweat glands, and salivary glands, which can exacerbate the severity of this form (1). The systemic form, which requires lifelong management, tends to have a more severe course. In contrast, the renal form often improves within the first two years of life. Type 1 PHA typically presents with symptoms of salt wasting, growth retardation, hyperkalemia, and acidosis similar to those seen in infants diagnosed with congenital adrenal hyperplasia (CAH) (2). Decreased sodium reabsorption from epithelial cells and the cortical collecting duct leads to volume depletion, thereby reducing the electrochemical gradient that normally supports potassium and hydrogen ion secretion. Besides renal dysfunction, the systemic form of Type 1 PHA is also associated with respiratory tract infections and a positive sweat test (3). Type 2 PHA, known as Gordon syndrome or familial hyperkalemic hypertension, is characterized by hypertension, hyperkalemia, metabolic acidosis, normal kidney function, low-normal plasma renin activity, and aldosterone concentration (4). Type 2 PHA exhibits autosomal dominant inheritance.

This article discusses our experience in managing a patient with PHA due to an *SCNN1B* variant, highlighting the challenges encountered in clinical management.

### Case Report

A 7-day-old female infant, born via repeat cesarean section from the second pregnancy of a 23-year-old mother, presented to the hospital with symptoms of vomiting, pallor, lethargy, poor feeding, and sleepiness. The infant was born at term, weighing 3500 grams (between the 50th and 90th percentile), with a length of 51 cm (50th percentile) and a head circumference of 36 cm (50th percentile). Due to the findings of hyponatremia and hyperkalemia upon initial evaluation, a preliminary diagnosis of congenital adrenal hyperplasia (CAH) was considered, prompting referral to our center. There is a history of consanguinity (second-degree cousin) between the mother and father. The infant has a healthy 3.5-year-old male sibling.

On physical examination, her general condition was fair to poor, with altered skin turgor and milia and pustular erythematous rash on her face and neck. There were no ambiguous genitalia or hyperpigmentation noted. Examination of other systems was unremarkable. The patient's laboratory test results are shown in **Table 1**. Venous blood gas analysis showed a pH of 7.36, bicarbonate (HCO<sub>3</sub>) of 11.5 mmol/L, and base excess (BE) of -11.3 mmol/L. Due to hyperkalemia, the patient was started on appropriate fluid therapy and received treatments including calcium gluconate, glucose-insulin infusion, NaHCO<sub>3</sub> infusion, and inhaled salbutamol. A 25-mg loading dose of IV

hydrocortisone was administered, followed by 5 mg of IV stress dosing every 6 hours. Additionally, fludrocortisone 0.1 mg twice daily was initiated; however, despite these interventions, the patient's hyperkalemia and hyponatremia remained resistant. Oral calcium polystyrene sulfonate at a dose of 1 g/kg/day and oral salt supplementation (4x1 g/day) were gradually increased. Laboratory findings upon admission to our clinic included spot urine analysis showed sodium levels of 156 mEq/L (normal range: 54-150 mEq/L) and potassium levels of 3.5 mEq/L (normal range: 6.7-21.3 mEq/L) concurrent with serum sodium of 118 mmol/L and potassium of 9.8 mmol/L. The calculated transtubular potassium gradient was found to be low. Based on these laboratory results, hydrocortisone therapy was not continued. Fludrocortisone therapy was continued but did not provide benefit. Considering the patient's presentation in the neonatal period, laboratory findings of hyponatremia and hyperkalemia with increased urinary sodium excretion, elevated aldosterone levels, and normal blood pressure, systemic PHA was suspected. Secondary PHA was ruled out based on normal urine analysis, urine culture, and urinary system ultrasonography. Despite increasing the dose of calcium polystyrene sulfonate to 4 g/kg/day and other conventional treatments, the patient's hyperkalemia persisted, necessitating peritoneal dialysis. Potassium levels decreased from 8.2 mmol/L pre-dialysis to 4.3 mmol/L on follow-up. The patient remained stable on treatment with 4x1 g oral salt and 10 g/day of calcium polystyrene sulfonate. She gained 1360 grams during hospitalization, weighing 4620 grams at discharge on the 37th day, with treatment being appropriately managed. Our patient was diagnosed with electrolyte imbalance at 2 months of age, pneumonia at 3.5 months, and again with electrolyte imbalance at 6 months, requiring hospitalization and treatment each time.

At 8 months of age, the patient was brought to the emergency department due to vomiting and diarrhea. Initial tests upon arrival showed sodium (Na) at 123 mmol/L and potassium (K) at 10.7 mmol/L. Due to respiratory distress and desaturation, the patient underwent endotracheal intubation and was admitted to the pediatric intensive care unit. Following 55 days of hospitalization for pneumonia, the patient passed away at 10 months of age (**Figure 1**).

Considering the clinical and laboratory findings suggestive of systemic Type 1 pseudohypoaldosteronism (PHA), the patient's related genes were examined using next-generation sequencing. Informed consent was obtained from the parents for this study. A homozygous variant c.1234dup (p.Glu412Glyfs\*39) in exon 8 of the *SCNN1B* gene was identified in the patient. This variant, a nucleotide duplication, has not been reported in population genetics studies and is classified as 'likely pathogenic' according to ACMG (American College of Medical Genetics) criteria. It was planned to conduct genetic testing for the patient's family as well, but it has not been sent yet.

### Discussion

In this article, we present our observations and the challenges encountered during the treatment process of a newborn with multisystem pseudohypoaldosteronism type 1 (PHA). Systemic Type 1 PHA is a rare, life-threatening condition. In the neonatal period, salt-wasting syndromes present with various clinical manifestations. Patients may present with nonspecific symptoms such as vomiting, weakness, feeding difficulties, failure to thrive, and increased tendency to sleep, or severe dehydration leading to shock (5). Typically, neonates presenting with these symptoms may initially be misdiagnosed with conditions such as congenital adrenal hyperplasia (CAH) due to 21-hydroxylase or 3-beta-hydroxysteroid dehydrogenase deficiency, or primary hypoaldosteronism causing salt loss in the neonatal period. The diagnosis of Type 1 PHA relies on high plasma aldosterone and renin levels, especially when high-dose mineralocorticoid therapy fails to correct potassium and salt imbalance. Additionally, measurements of 17-hydroxyprogesterone, ACTH, cortisol, renin, and aldosterone levels provide clues in distinguishing between CAH and Type 1 PHA (6). Our patient presented with hyponatremia and hyperkalemia alongside normal genitalia. Hydrocortisone and fludrocortisone were initiated until adrenal androgen results were obtained. The diagnosis of systemic Type 1 PHA was confirmed as adrenal hormone levels remained within normal ranges during follow-up. Differential diagnosis in our case included transient aldosterone resistance secondary to urinary tract infection, which was ruled out due to normal urine analysis, urine culture, and urinary system ultrasonography. The co-occurrence of high aldosterone levels with hyponatremia and hyperkalemia supported renal aldosterone resistance guiding our patient's treatment.

Type 1 PHA is classified into renal (OR) and systemic (OD) forms based on mutations in the *NR3C2* gene encoding MR or *SCNN1A*, *SCNN1B*, and *SCNN1G* genes encoding ENaC subunits. The systemic form of Type 1 PHA leads to systemic salt loss involving kidneys, colon, sweat, and salivary glands (7). In our case, a homozygous variant c.1234dup (p.Glu412Glyfs\*39) was identified in exon 8 of the *SCNN1B* gene. The *SCNN1B* gene, comprising 13 exons and encoding a transmembrane protein with two transmembrane segments totaling 640 amino acids (8), has been associated with pathogenic variants linked to Type 1 PHA and Liddle syndrome. It is anticipated that the identified homozygous variant in the *SCNN1B* gene at nucleotide position 1234, a duplication variant, affects protein functions. This variant has not been previously reported in the literature.

A case with a homozygous mutation detected in the promoter region of the ENaC in the *SCNN1B* gene has reported recurrent lung infections similar to our patient. However, in this case, over time, the frequency and severity of these respiratory diseases showed a tendency to decrease, and the lung condition stabilized after the age of 6 [9]. In another study reporting a case with a mutation detected in the *SCNN1B* gene, additional clinical features included persistent clear nasal discharge, frequent lower respiratory tract infections associated with wheezing, and developmental delay. This case, which required a gastrostomy at 14 months, showed a significant reduction in hospital admissions (1-2 per year) following the gastrostomy, although recurrent lower respiratory tract infections were still reported despite being four years old now [10]. Similarly, another case reported recurrent chronic bronchitis attacks during childhood [11]. In another case with a homozygous c.1266-1G > C variant mutation in intron 8 of the *SCNN1B* gene, vomiting and feeding difficulties similar to those observed in our patient were reported [12]. The skin findings observed in our patient, which persist despite treatment, have also been observed in other patients with mutations in the *SCNN1B* gene. Belot et al. (13) observed bullous dermatitis, while Gopal-Kothandapani et al. (8) reported severe eczema. Similarly, another case with a homozygous mutation in the *SCNN1B* gene presented with features mimicking pustular miliaria rubra, crystal deposition on the forehead, Meibomian gland swelling on the eyelids, and dental-like protrusions (11). These skin and ocular findings can aid in distinguishing Type 1 PHA from other conditions causing salt loss like CAH, prompting the evaluation of serum electrolytes through blood tests (14). In the literature, gastrostomy has been required in four cases due to salt loss (10, 11, 13, 15). Although not needed in our patient, during episodes of vomiting, an orogastric tube was used to administer oral therapies. Hyperkalemia can be life-threatening due to the risk of cardiac arrhythmias. Publications have reported peritoneal dialysis being performed to correct hyperkalemia similar to our case (6, 8, 16-19).

Since systemic Type 1 PHA can be more refractory to treatment, it is essential to learn from less commonly known approaches; further endocrinology guidance for sodium polystyrene sulfonate (brand name: Kayexalate, kalexate, and kionex; molecular weight 70,000 atomic mass units; concentration 15 g/60 mL) administration in neonates and infants is necessary (20). There is limited guidance in the literature on specifically how to give sodium polystyrene sulfonate to neonates and infants and specifically safety of transitioning from decanting formula to giving it directly. Sodium polystyrene sulfonate dosing in several children between the ages of 1.75 and 3.25 years old ranged from 0.4 to 3.4 g/kg/day; however, the dosing and method of administration varied (2). Initial direct administration is not always feasible in neonates, to minimize risks such as GI bleeding (2). Sodium polystyrene sulfonate can effectively treat hyperkalemia in type 1 PHA, but it is not routinely available in our country. Therefore, we used calcium polystyrene sulfonate in the treatment of our patient.

### Conclusion

Clinical suspicion of PHA, aggressive treatment with IV hydration, sodium and bicarbonate supplementation, and correction of hyperkalemia are crucial. Adding patients' clinical symptoms and genetic changes to the literature, and establishing clearer links between reported mutations and clinical outcomes, will lead to earlier clinical diagnosis and effective genetic counseling for cases presenting with such complaints.

## Ethics

Patient Consent: Written consent was obtained from the parents.

## Authorship Contributions

Surgical and Medical Practices: Berna Singin, Zeynep Donbaloğlu, Ebru Barsal Çetiner, Kürşat Çetin, Nurten Özkan Zarif, Kıymet Çelik, Hale Tuhan, Mesut Parlak, Concept: Berna Singin, Zeynep Donbaloğlu, Ebru Barsal Çetiner, Kürşat Çetin, Hale Tuhan, Mesut Parlak, Design: Berna Singin, Zeynep Donbaloğlu, Ercan Mihçi, Mesut Parlak, Data Collection or Processing: Berna Singin, Zeynep Donbaloğlu, Ebru Barsal Çetiner, Kürşat Çetin, Nurten Özkan Zarif, Kıymet Çelik, Hale Tuhan, Mesut Parlak, Ercan Mihçi, Özden Altıok Clark, Analysis or Interpretation: Berna Singin, Mesut Parlak, Ercan Mihçi, Özden Altıok Clark, Literature Search: Berna Singin, Mesut Parlak, Writing: Berna Singin, Mesut Parlak

**Financial Disclosure:** The authors declared that this study received no financial support.

## References

1. Pujo L, Fagart J, Gary F, Papadimitriou DT, Claës A, Jeunemaître X, et al. Mineralocorticoid receptor mutations are the principal cause of renal type 1 pseudohypoaldosteronism. *Human mutation*. 2007;28(1):33-40.
2. Nur N, Lang C, Hodax JK, Quintos JB. Systemic pseudohypoaldosteronism type I: a case report and review of the literature. *Case Reports in Pediatrics*. 2017;2017.
3. Amin N, Alvi N, Barth J, Field H, Finlay E, Tyerman K, et al. Pseudohypoaldosteronism type 1: clinical features and management in infancy. *Endocrinology, Diabetes & Metabolism Case Reports*. 2013;2013(1).
4. Bonny O, Rossier BC. Disturbances of Na/K balance: pseudohypoaldosteronism revisited. *Journal of the American Society of Nephrology*. 2002;13(9):2399-414.
5. Akın MA, Çoban D, Kurtuluş S, Akın L, Akçakuş M. Yenidoğanda iki tuz kaybı olgusu: primer ve sekonder psödohipoaldosteronizm. *Erciyes Tıp Dergisi*. 2010;32(3):207-12.
6. Gao Z, Sun J, Cai C, Gong X, Ma L. Pseudohypoaldosteronism type 1b in fraternal twins of a Chinese family: report of two cases and literature review. *Archives of Endocrinology and Metabolism*. 2023;67:e000620.
7. Riepe FG. Clinical and molecular features of type 1 pseudohypoaldosteronism. *Hormone research*. 2009;72(1):1-9.
8. Gopal-Kothandapani JS, Doshi AB, Smith K, Christian M, Mushtaq T, Banerjee I, et al. Phenotypic diversity and correlation with the genotypes of pseudohypoaldosteronism type 1. *Journal of Pediatric Endocrinology and Metabolism*. 2019;32(9):959-67.
9. Thomas CP, Zhou J, Liu KZ, Mick VE, MacLaughlin E, Knowles M. Systemic pseudohypoaldosteronism from deletion of the promoter region of the human  $\beta$  epithelial Na<sup>+</sup> channel subunit. *American journal of respiratory cell and molecular biology*. 2002;27(3):314-9.
10. Edelheit O, Hanukoglu I, Gizewska M, Kandemir N, Tenenbaum-Rakover Y, Yurdakök M, et al. Novel mutations in epithelial sodium channel (ENaC) subunit genes and phenotypic expression of multisystem pseudohypoaldosteronism. *Clinical Endocrinology*. 2005;62(5):547-53.
11. Nobel YR, Lodish MB, Raygada M, Del Rivero J, Faucz FR, Abraham SB, et al. Pseudohypoaldosteronism type 1 due to novel variants of SCNN1B gene. *Endocrinology, diabetes & metabolism case reports*. 2016;2016(1).
12. Dogan CS, Erdem D, Mesut P, Merve A, Sema A, Iffet B, et al. A novel splice site mutation of the beta subunit gene of epithelial sodium channel (ENaC) in one Turkish patient with a systemic form of pseudohypoaldosteronism type 1. *Journal of Pediatric Endocrinology and Metabolism*. 2012;25(9-10):1035-9.
13. Belot A, Ranchin B, Fichtner C, Pujo L, Rossier BC, Ljutikus A, et al. Pseudohypoaldosteronisms, report on a 10-patient series. *Nephrology Dialysis Transplantation*. 2008;23(5):1636-41.
14. Reddy G, Panigrahy N. Unusual skin and eyelid changes in a neonate with pseudohypoaldosteronism. *Archives of Disease in Childhood-Fetal and Neonatal Edition*. 2023;108(3):285-.
15. Saxena A, Hanukoglu I, Saxena D, Thompson RJ, Gardiner RM, Hanukoglu A. Novel mutations responsible for autosomal recessive multisystem pseudohypoaldosteronism and sequence variants in epithelial sodium channel  $\alpha$ -,  $\beta$ -, and  $\gamma$ -subunit genes. *The Journal of Clinical Endocrinology & Metabolism*. 2002;87(7):3344-50.
16. Güran T, Değirmenci S, Bulut İK, Say A, Riepe FG, Güran Ö. Critical points in the management of pseudohypoaldosteronism type 1. *Journal of Clinical Research in Pediatric Endocrinology*. 2011;3(2):98.
17. Saravanapandian N, Paul S, Matthai J. Pseudohypoaldosteronism type 1: a rare cause of severe dyselectrolytemia and cardiovascular collapse in neonates. *Journal of Clinical Neonatology*. 2012;1(4):224-6.
18. Sharma R, Pandey M, Kanwal SK, Zennaro MC. Pseudohypoaldosteronism type 1: management issues. *Indian pediatrics*. 2013;50:331-3.
19. Küçükali GK, Cetinkaya S, Tunç G, Oğuz MM, Çelik N, Akkaş KY, et al. Clinical management in systemic type pseudohypoaldosteronism due to SCNN1B variant and literature review. *Journal of clinical research in pediatric endocrinology*. 2021;13(4):446.
20. Alkhatib EH, Bartlett D, Kanakatti Shankar R, Regier D, Merchant N. Case report: Early molecular confirmation and sodium polystyrene sulfonate management of systemic pseudohypoaldosteronism type I. *Frontiers in endocrinology*. 2024;14:1297335.

**Table 1.** Patient's laboratory results

|                        | <b>Result</b> | <b>Normal Range</b> |
|------------------------|---------------|---------------------|
| Na (mmol/L)            | 118           | 136-145             |
| K (mmol/L)             | 9.8           | 3.5-5.1             |
| BUN (mg/dL)            | 25            | 4-19                |
| Creatinine (mg/dL)     | 0.52          | 0.17-0.42           |
| Uric acid (mg/dL)      | 6.5           | 2.4-5.7             |
| 17-OHP (ng/mL)         | 9.6           | 0.051-2.35          |
| ACTH (ng/L)            | 5.66          | 7.2-63.3            |
| Serum cortisol (ug/dL) | 32.9          | 4.82-19.5           |
| Renin (ng/mL/hour)     | 13.1          | 2.4-37              |
| Aldosterone (ng/dL)    | 200           | 3-16                |

Na: Sodium, K: Potassium, BUN: Blood urea nitrogen, 17-OHP: 17-Hydroxyprogesterone, ACTH: Adrenocorticotrophic hormone

Uncorrected proof

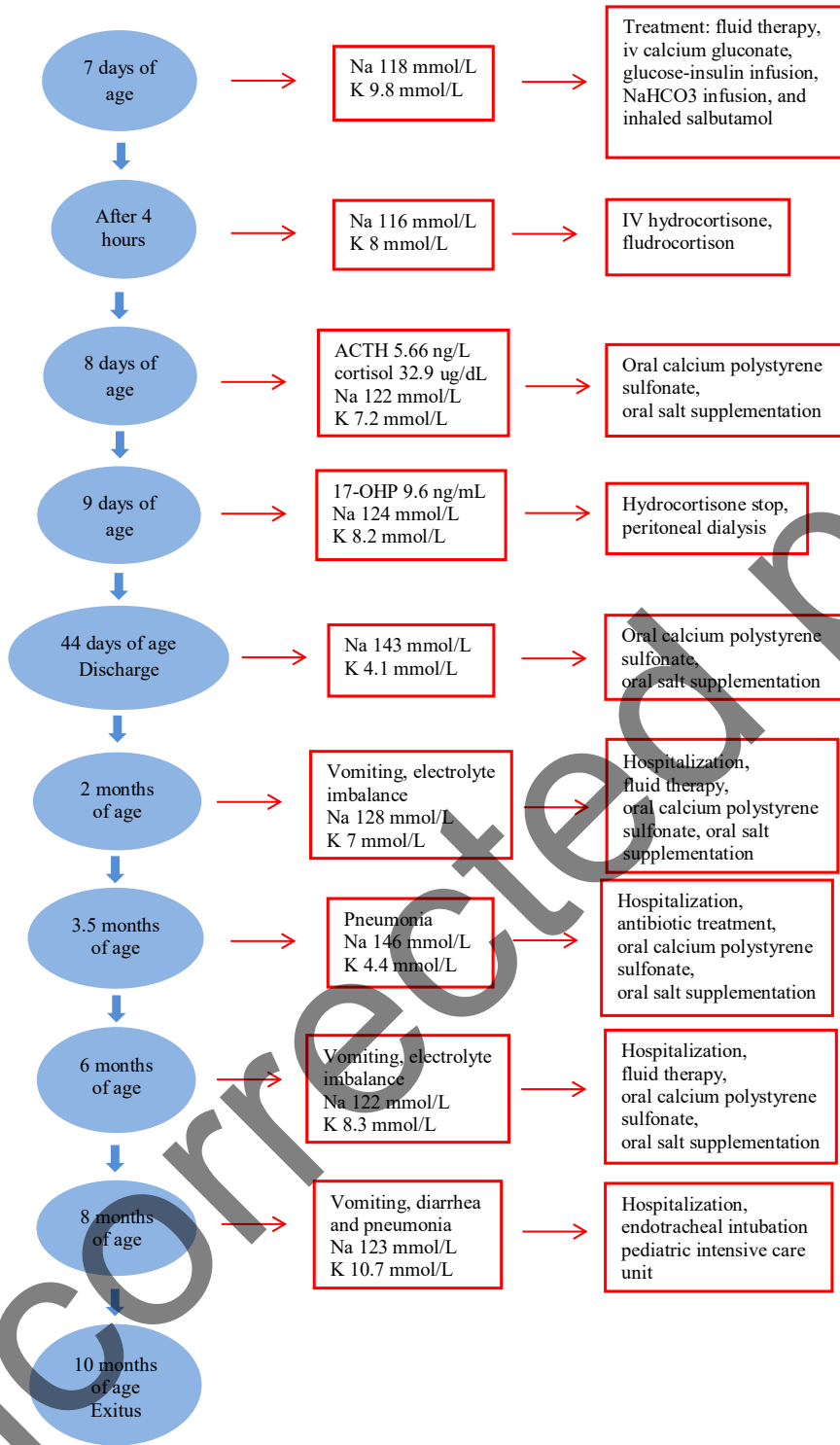


Figure 1. Timeline of case