

Case Report

Atypical Presentation and Course of ACTH-independent Cushing's Syndrome in Two Families

Kübra Yüksek Acinikli¹, Sezer Acar², Ahu Paketçi³, Özgür Kırbıyık⁴, Mert Erbaş⁵, Özge Besci¹, Gözde Akın Kağızmanlı¹, Deniz Kızmazoğlu⁶, Oktay Ulusoy⁷, Erdener Özer⁸, Kutsal Yörükoğlu⁸, Ayhan Abacı¹, Handan Güleriyüz⁹, Ece Böber¹, Korcan Demir¹

¹Pediatric Endocrinology, Dokuz Eylül University, Faculty of Medicine, İzmir, Turkey

²Pediatric Endocrinology, Manisa City Hospital, Manisa, Turkey

³Pediatric Endocrinology, Medipol University Hospital, İstanbul, Turkey

⁴Genetic Diagnosis Center, Tepecik Training and Research Hospital, İzmir, Turkey

⁵Pediatric Endocrinology, Dr. Behçet Uz Children's Education and Research Hospital, İzmir, Turkey

⁶Pediatric Oncology, Dokuz Eylül University Institute of Oncology, İzmir, Türkiye

⁷Pediatric Surgery, Dokuz Eylül University, Faculty of Medicine, İzmir, Turkey

⁸Department of Pathology, Dokuz Eylül University, Faculty of Medicine, İzmir, Turkey

⁹Department of Radiology, Division of Pediatric Radiology, Dokuz Eylül University, Faculty of Medicine, İzmir, Turkey

What is already known on this topic?

Primary pigmented nodular adrenocortical disorder (PPNAD), which is rarely seen in children while it is the most prevalent cause of ACTH-independent Cushing's syndrome (CS), is typically a micronodular disease and mainly associated with Carney complex (CNC). Carney complex (CNC) is a rare autosomal dominant syndrome, characterized by pigmented lesions of the skin and mucosa, cardiac, cutaneous and other myxomas and multiple endocrine tumors.

What this study adds?

The findings of reported families provide information for a better understanding of the genetic pathogenesis, diagnosis and clinical management of CNC. Analytic variability in ACTH assays should be kept in mind during interpretation of ACTH levels. One case developed Hodgkin lymphoma five years after adrenalectomy, this association was not previously reported with CNC. Two cases had macronodules contrary to what is generally seen in cases with PPNAD.

Abstract

Primary pigmented nodular adrenocortical disease (PPNAD) is a rare genetic disease mainly associated with Carney complex (CNC), which is caused by germline mutations of the regulatory subunit type 1A (RI α) of the cAMP-dependent protein kinase (PRKARIA) gene. We report three cases suffering from CNC with unique features in diagnosis and follow-up. All cases had obesity and a cushingoid appearance and exhibited laboratory characteristics of hypercortisolism. However, biochemical and radiological examinations initially suggested Cushing's disease in one case. All of the cases were treated surgically; two of them underwent bilateral adrenalectomy at once, one of them had unilateral adrenalectomy at first but required contralateral adrenalectomy after nine months. Contrary to what is usually known regarding PPNAD, the adrenal glands of two cases (case 2 and 3) had a macronodular morphology. Genetic analyses revealed pathogenic variants in PRKARIA (case 1: c.440+5 G>A, not reported in the literature; cases 2 and 3: c.349G>T, p.V117F). One case developed Hodgkin lymphoma five years after adrenalectomy, this association was not previously reported with CNC. The findings of these families provide important information for a better understanding of the genetic pathogenesis, diagnosis, and clinical management of CNC. Hodgkin lymphoma may be a component of CNC.

Keywords: Cushing's disease, cancer, myxoma, lentigo, PEG precipitation, macronodule

Korcan Demir MD, Pediatric Endocrinology, Dokuz Eylül University, Faculty of Medicine, İzmir, Turkey

+90 (232) 412 22 22

korcandemir@gmail.com

0000-0002-8334-2422

19.09.2023

10.12.2023

Published: 12.12.2023

Introduction

Endogenous Cushing's syndrome in children is rare, with an incidence of 1–1.5 per million population per year. Adrenocorticotropic hormone (ACTH)-independent Cushing's syndrome accounts for 15–20% of endogenous Cushing's syndrome (1). Bilateral nodular adrenocortical diseases have been detected in 1–2% of them, resulting in ACTH-independent Cushing's syndrome (2). In primary pigmented nodular adrenocortical disease (PPNAD), both adrenal glands are involved, and there are small brown-black nodules separated by the atrophic adrenal cortex. Nodules are typically smaller than 1 cm and demonstrate micronodular hyperplasia (3). Carney complex (CNC) is a rare autosomal dominant syndrome characterized by pigmented lesions of the skin and mucosa, cardiac, cutaneous, and other myxomas, and multiple endocrine tumors, the most common of which is PPNAD (4). CNC is caused by mutations in the *PRKARIA* (OMIM 188830) coding for the regulatory subunit type 1a (RI α) of protein kinase A (PKA). To establish a diagnosis of CNC, a patient must exhibit two of the disease's manifestations or exhibit one of these manifestations and have an affected first-degree relative or an inactivating *PRKARIA* mutation. No direct correlation has been identified between all *PRKARIA* mutations and the various phenotypes yet (5).

The present work describes three cases who had PPNAD. Two of the cases were distantly related, and we present two pedigrees involving cases and currently healthy *PRKARIA* mutation carriers. The cases had unique diagnostic and follow-up features; to the best of our knowledge, this report presents the first CNC case who developed Hodgkin lymphoma at follow-up.

Case Reports

Case characteristics are shown in Table 1 and pedigrees in Figure 1.

Case 1

The proband was an 11-year-old female; she presented to our institution with weight gain over the last 2 years. She was pubertal. The family history revealed no consanguinity. On physical examination, her height, weight, and body mass index (BMI) were 132.5 cm [-1.5 standard

deviation (SD) score), 44.8 kg (0.92 SD score), and 25.5 (+1.8 SD score)], respectively. Moon face, abdominal adiposity, buffalo hump, acne, and striae were evident. The hormonal assessment showed a suppressed plasma ACTH in the presence of high morning serum cortisol and an altered circadian cortisol level. The hormonal and clinical signs indicated ACTH-independent CS. A computer tomography (CT) scan of the adrenals revealed bilateral micronodular hyperplasia (shown in Figure 3A). PPNAD was suspected, and bilateral adrenalectomy was performed. Hydrocortisone and fludrocortisone were initiated. The histopathological findings showed numerous cortical hyperplastic nodules (less than 4 mm) compatible with PPNAD. She progressively lost weight, and signs of CS regressed. The molecular genetic analysis of *PRKARIA* identified a heterozygous splice site mutation within exon 4a [c.440+5 G>A, pathogenic according to the American College of Medical Genetics and Genomics (ACMG)], which was not reported in the medical literature. This variation has not been associated with any protein alterations. Nevertheless, the occurrence of a different variation within the same identical exon (c.440+5 G>C) was reported to result in a premature stop codon (TGA) and modification of the secondary structure of the RI α domain (6). Regarding CNC, cardiac examination and thyroid ultrasound (US) were normal, and there were no signs of skin lesions. Other pituitary hormone levels were normal. Genetic analysis of her mother (44 years old) and maternal aunt (35 years old) was performed, and they had the same variant in *PRKARIA* without any symptoms or signs of CNC. Her father and other family members could not undergo genetic analysis due to social reasons. Reportedly, subjects III.11, IV.4, and IV.5 were diagnosed with CS and had an adrenalectomy. At the age of 16 years, the patient developed persistent cervical and supraclavicular lymphadenopathy associated with weight loss and was diagnosed with nodular sclerosing type Hodgkin's lymphoma five years after adrenalectomy. At the most recent follow-up of Case 1, she was 17 years and 8 months old; her physical examination was normal (weight: 45 kg (-1.75 SD score), height: 150 cm (-2.21 SD score), BMI: 20 kg/m² (-0.25 SD score), and other manifestations of CNC were not present.

Case 2

This case was a 16-year-old female who presented with a 5-year history of significant weight gain, hirsutism, and irregular menstrual periods. Pubertal development was already complete, with spontaneous menarche starting at 12 years. The family history revealed no consanguinity. On physical examination, her height, weight, and BMI were 147.5 cm (-2.58 SD score), 85.6 kg (3.29 SD score), and 39.5 (3.83 SD score), respectively. She displayed striae, moon face, abdominal adiposity, buffalo hump, acne, and hirsutism. There were no lentiginos or blue nevi on skin examination. Serum and 24-hour urinary cortisol levels were high. At first, plasma ACTH level (Siemens, a solid phase, two-site enzyme chemiluminescent system, IMMULITE® 2000 XPI) was found to be 14 pg/mL (normal, 7-63 pg/mL). Pituitary magnetic resonance imaging (MRI) revealed an adenoma (4 mm). High dose dexamethasone suppression test revealed not suppressed ACTH level of 10.6 pg/mL. Clinical and biochemical incompatibility suggested ACTH interference and ACTH level was undetectable after polyethylene glycol precipitation (PEG). Similarly, ACTH level was too low (<1 pg/mL) when measured with a different analytical platform (Roche Cobas E411 Diagnostics, a solid-phase, two site electrochemiluminescence immunoassay platform). Adrenal CT scanning showed bilateral nodular lesions characteristic of hyperplasia, which were more prominent and macronodular on the left adrenal gland (shown in Figure 2B). Bilateral adrenalectomy was performed. Hydrocortisone and fludrocortisone were initiated. The histopathological findings showed PPNAD with bilateral micro- and macronodules (greater than 10 mm), while revealing no discernible signs of necrotic or hemorrhagic regions (shown in Figures 3B and 4). The molecular genetic analysis of the *PRKARIA* gene identified a heterozygous, previously reported c.349G>T (p.V117F, pathogenic according to the ACMG criteria). Additional investigations for CNC features were negative. Her mother, father, and brother underwent genetic analysis and only her father had the same variant without any symptoms. At the most recent follow-up of Case 2, she was 21 years and 6 months old, her blood pressure was normal without any medication but she was obese (weight: 72.5 kg, height: 149 cm, BMI: 32.4 kg/m²). Other manifestations of CNC were not present. The size of pituitary adenoma did not change during follow-up.

Case 3

Case 3 was a 12-year-old female who presented to another institution complaining of hirsutism, significant acne, and weight gain over the preceding two years. Her parents were second cousins. On physical examination, her height, weight, and BMI were 146 cm (-1.16 SD score), 102.4 kg (4.68 SD score), and 48 (+4.5 SD score), respectively. Pubertal development was Tanner stage 3, without menarche. She displayed striae, a moon face, abdominal adiposity, and a buffalo hump, there were no lentiginos or blue nevi on skin examination. She had persistent hypertension and was on enalapril, spironolactone, and valsartan treatments. Hormonal assessment showed a suppressed plasma ACTH in the presence of high serum cortisol with increased levels of 24-hour urinary free cortisol. Adrenal CT evaluation revealed bilateral nodular lesions, which were more prominent on the left (shown in Figure 2C). She had undergone a left-side adrenalectomy at another institution. However, her clinical picture and hypercortisolism did not improve, and she was referred to our center. Hormonal assessment showed a suppressed plasma ACTH levels in the presence of high serum cortisol. A right-side adrenalectomy was performed at our institution nine months after the first surgery. Hydrocortisone and fludrocortisone were initiated. Histopathological assessment revealed bilateral micro- and macronodular hyperplasia. *PRKARIA* analysis detected the same mutation as in Case 2 (c.349G>T, p.V117F). Her mother and brother had the same variant without any symptoms or signs of CNC. Her maternal aunt, who had the same *PRKARIA* mutation, was diagnosed with ACTH-independent CS. Her adrenal CT revealed bilateral adenoma (right 25x27 mm, left 10x10 mm). She underwent a right adrenalectomy in another center, and histopathological assessment revealed adrenocortical oncocytoma. At the most recent follow-up of Case 3, she was 14 years and 4 months old, her blood pressure was normal without any medication, but she was obese (weight: 93.7 kg (+4.2 SD score), height: 152.5 cm (-1.59SD score), BMI: 40.2 kg/m² (+4.2 SD score)) and had hirsutism. Other manifestations of CNC were not present.

Follow up

We recommended annual laboratory and imaging evaluations for both affected subjects and the asymptomatic carriers, with an echocardiogram for cardiac myxoma, a thyroid ultrasound for thyroid nodules, a testicular ultrasound for boys, and the measurement of insulin-like growth factor-1 and prolactin beginning in adolescence to screen for pituitary overactivity. For asymptomatic carriers, an annual measurement of 24-hour urinary free cortisol (UFC) excretion was planned. Until now, we have not identified any additional characteristics of CNC in both affected subjects and asymptomatic carriers (7).

Discussion

The diagnosis of CS is not straightforward; accordingly, approximately 2.5 to 3 years of delay are reported in the literature (8). The diagnosis of CS was further difficult in case 2 due to falsely nonsuppressed ACTH levels. Available ACTH assays present considerable differences in terms of sensitivity and lead to a wide variability in ACTH measurements, especially when confronted with low concentrations of ACTH. In the present case, measurement of the ACTH level was initially conducted with a kit that was reported to fail in detecting low ACTH levels in 19% of cases in a multicenter study (9)(10). Treatment of plasma and serum samples with PEG has been shown to precipitate immunoglobulins, including heterophile antibodies. Falsely high values are prevented, and the real result is achieved (11)(10). Thus, a PEG procedure was performed in our patient's serum, and an undetectable ACTH level was demonstrated. Additionally, suppressed ACTH levels were confirmed with a different analytical platform. Regardless of their sensitivity and specificity, immunoassays are susceptible to occasional analytical errors. An astute clinician should keep in mind the potential for interference in cases where there is a discrepancy between clinical and laboratory findings.

A contrast-enhanced CT scan should be the next diagnostic step after hormonal evaluation in patients with ACTH-independent CS(1). The appearance of the adrenal glands on imaging in patients with PPNAD is often initially interpreted as normal, which differs from other

ACTH-independent disorders where relatively large tumors are easily seen. It is crucial that the clinician and radiologist have expertise in evaluating radiological findings in these cases. Nodules are typically less than 1 cm in size (micronodules)(12). However, histopathological evaluation of the adrenal glands in cases 2–3 demonstrated macronodules. Contrary to what is generally known, macronodular appearance can rarely be detected in cases of PPNAD. According to the report of 11 patients with PPNAD due to *PRKARIA* variants, a patient (26 years of age) had macronodules (2.5 cm), while three (between 25 and 55 years of age) of four patients with PPNAD without a *PRKARIA* mutation had macronodules (3). An 18-year-old female who had a monoallelic (c.102G>A) germline *PRKARIA* mutation was reported to have macronodular PPNAD. In addition, a somatic mutation in *PRKARIA* (16-bp deletion of the acceptor splice site of exon 4B, IVSdel-17→-2) was found in the macronodule. This somatic mutation was not present in the tissue adjacent to this nodule, in the left adrenal, or in leukocyte DNA (13). Exact etiology of macronodules in PPNAD is unclear, in general, somatic *CTNNB1* mutations are suggested to play a role in the formation of macronodules by accumulation of β -catenin (5).

The variant in case 1 (c.440+5 G>A) was also present in her asymptomatic mother and maternal aunt, while individuals III.11, IV.4, and IV.5 within this family were reported to have Cushing's syndrome (CS) and underwent adrenalectomy. However, as these patients reside in another country, we were unable to gather additional clinical and genetic information about them. Typically, the overall penetrance of the Carney complex (CNC) in individuals with a pathogenic *PRKARIA* variant exceeds 95% by the age of 50. However, certain splice site variants may lead to a milder phenotype or reduced penetrance of CNC (5). To date, there is only one report in the literature of the *PRKARIA* variant in cases 2 and 3, and in these cases, the adrenal phenotype was highly variable (14). According to this report, the c.349G>T splice site mutation is predicted to lead to exon 4 skipping, and the resulting frameshift would lead to a premature stop codon. The *PRKARIA* mutation was found in three asymptomatic individuals within this familial cohort, who did not exhibit any clinical signs associated with Carney complex (CNC). The authors concluded that the c.349G>T variation has low penetrance, resulting in incomplete clinical expression. The absence of CNC symptoms in asymptomatic carriers might be related to both the young age of the carriers and the low penetrance of some variants in *PRKARIA*.

In addition, Case 1 developed lymphoma during follow-up. *PRKARIA* is the gene encoding the type 1A regulatory subunit of PKA, which modulates various events during cell proliferation along with cAMP, and deregulation of these effector molecules is associated with the development of different cancers via multiple pathways (15). Functionally, loss of *PRKARIA* is associated with excess PKA signaling in tumors from patients, although the exact mechanism by which this aberrant signaling causes tissue-specific tumorigenesis is unknown (16). Patients with a *PRKARIA* mutation were more likely to develop other cancers, including growth hormone-secreting pituitary tumors, gonadal tumors, and thyroid neoplasms, at an earlier age (8). However, Hodgkin's lymphoma has never been reported in the context of CNC, despite the fact that PKA is obviously involved in the regulation of the immune system (17). To the best of our knowledge, there is only one animal study regarding this association. In a mouse model for the CNC, mice with antisense-*Prkar1a* expression were found to have B-cell lymphoma, but the *Prkar1a* knock-out mice did not develop such a proliferative disease. In addition, *Prkar2a*-knockout mice (absence of another PKA subunit) developed lymphoma (16). In view of the abovementioned data, we think that the *PRKARIA* mutation in Case 1 might have played a role in her Hodgkin's lymphoma.

In summary, our study broadens the genotypic and phenotypic spectrum of *PRKARIA* mutations associated with CNC. For the first time, the coexistence of PPNAD and lymphoma has been reported. The findings of these families provide important information for a better understanding of the genetic pathogenesis, diagnosis, and clinical management of CNC.

References

1. Ferrigno R, Hasenmajer V, Caiulo S, Minnetti M, Mazzotta F, Storr HL, et al. Paediatric Cushing's disease: Epidemiology, pathogenesis, clinical management and outcome. *Reviews in endocrine & metabolic disorders*. 2021 Dec 1;22(4):817–35.
2. Maillet M on primary micronodular bilateral adrenocortical diseases, Bourdeau I, Lacroix A. Update on primary micronodular bilateral adrenocortical diseases. *Current opinion in endocrinology, diabetes, and obesity*. 2020 Jun 1;27(3):132–9.
3. Vezzosi D, Tenenbaum F, Cazabat L, Tissier F, Bienvenu M, Carrasco CA, et al. Hormonal, Radiological, NP-59 Scintigraphy, and Pathological Correlations in Patients With Cushing's Syndrome Due to Primary Pigmented Nodular Adrenocortical Disease (PPNAD). *The Journal of clinical endocrinology and metabolism*. 2015 Nov 1;100(11):4332–8.
4. Çakır AD, Turan H, Celkan T, Çomunoğlu N, Erkan O, Evliyaoğlu O. An unusual presentation of carney complex. *JCRPE Journal of Clinical Research in Pediatric Endocrinology*. 2020;12(1):117–21.
5. Bertherat J, Horvath A, Groussin L, Grabar S, Boikos S, Cazabat L, et al. Mutations in regulatory subunit type 1A of cyclic adenosine 5'-monophosphate-dependent protein kinase (PRKARIA): Phenotype analysis in 353 patients and 80 different genotypes. *Journal of Clinical Endocrinology and Metabolism*. 2002;94(6):2085–91.
6. Fu J, Lai F, Chen Y, Wan X, Wei G, Li Y, et al. A novel splice site mutation of the PRKARIA gene, C.440+5 G>C, in a Chinese family with Carney complex. *Journal of Endocrinological Investigation*. 2018;41(8):909–17.
7. Stratakis CA. Carney Complex: a familial lentiginosis predisposing to a variety of tumors. *Reviews in endocrine & metabolic disorders*. 2016 Sep 1;17(3):367–73.
8. Stratakis CA, Kirschner LS, Carney JA. Clinical and Molecular Features of the Carney Complex: Diagnostic Criteria and Recommendations for Patient Evaluation. *The Journal of Clinical Endocrinology & Metabolism*. 2001;86(9):4041–6.
9. Giraldi FP, Sacconi A, Cavagnini F. Assessment of ACTH assay variability: A multicenter study. *European Journal of Endocrinology*. 2011;164(4):505–12.
10. Greene LW, Geer EB, Page-Wilson G, Findling JW, Raff H. Assay-specific spurious ACTH results lead to misdiagnosis, unnecessary testing, and surgical misadventure - A case series. *Journal of the Endocrine Society*. 2019;3(4):763–72.
11. Özgen Saydam B. Adrenocorticotrophic Hormone Immunoassay Interference in a Patient with Subclinical Hypercortisolism. *Acta Endocrinologica (Bucharest)*. 2020;16(3):379–82.
12. Stratakis CA. Adrenocortical tumors, primary pigmented adrenocortical disease (PPNAD)/Carney complex, and other bilateral hyperplasias: The NIH studies. *Hormone and Metabolic Research*. 2007;39(6):467–73.
13. Groussin L, Jullian E, Perlempine K, Louvel A, Leheup B, Luton JP, et al. Mutations of the PRKARIA gene in Cushing's syndrome due to sporadic primary pigmented nodular adrenocortical disease. *Journal of Clinical Endocrinology and Metabolism*. 2002;87(9):4324–9.
14. Storr HL, Metherell LA, Dias R, Savage MO, Rasmussen SK, Clark AJL, et al. Familial isolated primary pigmented nodular adrenocortical disease associated with a novel low penetrance PRKARIA gene splice site mutation. *Hormone Research in Paediatrics*. 2010;73(2):115–9.
15. Caretta A, Mucignat-Caretta C. Protein kinase a in cancer. *Cancers*. 2011;3(1):913–26.
16. Kirschner LS, Kusewitt DF, Matyakhina L, Towns WH, Carney JA, Westphal H, et al. A mouse model for the carney complex tumor syndrome develops neoplasia in cyclic AMP-responsive tissues. *Cancer Research*. 2005;65(11):4506–14.
17. Torgersen KM, Vang T, Abrahamson H, Yaqub S, Taskén K. Molecular mechanisms for protein kinase A-mediated modulation of immune function. *Cellular Signalling*. 2002;14(1):1–9.

Table 1. Case characteristics

	Case 1	Case 2*	Case 3*
Gender	Female	Female	Female
Age (years)	11	16	12
Serum cortisol (µg/dl)			
Morning, basal	17.8	30	25
Midnight (at 23:00)	15	NA	19
Morning, after 1 mg dexamethasone	17.8	13.8	13
24 h UFC (µg/m²/day, N:<70)	NA	207	233
ACTH (pg/ml, N:0-63)	<5	<1	<5
Adrenal CT scan	Symmetrical, bilateral nodular hyperplasia (bilateral micronodular)	Asymmetrical (L>R) bilateral nodular hyperplasia (left side macronodular)	Asymmetrical (L>R), bilateral nodular hyperplasia (left side macronodular)
PRKARIA variant	c.440+5G>A	c.349G>T	c.349G>T
IGF-1 (ng/mL, N: 143-506)	NA	215	203
DHEA-S(µg/dl, N:25-460)	NA	169	345
Echocardiography	Normal	Normal	Minimal Hypertrophic IVS
Thyroid Ultrasound	Normal	Normal	Normal

Abbreviations: UFC, urinary free cortisol; CT: computed tomography; IGF-1; Insulin Like Growth Factor-1; DHEAS: dehydroepiandrosterone, L, left; NA, not available; R, right; IVS, interventricular septum

* Cases 2-3 were distant relatives.

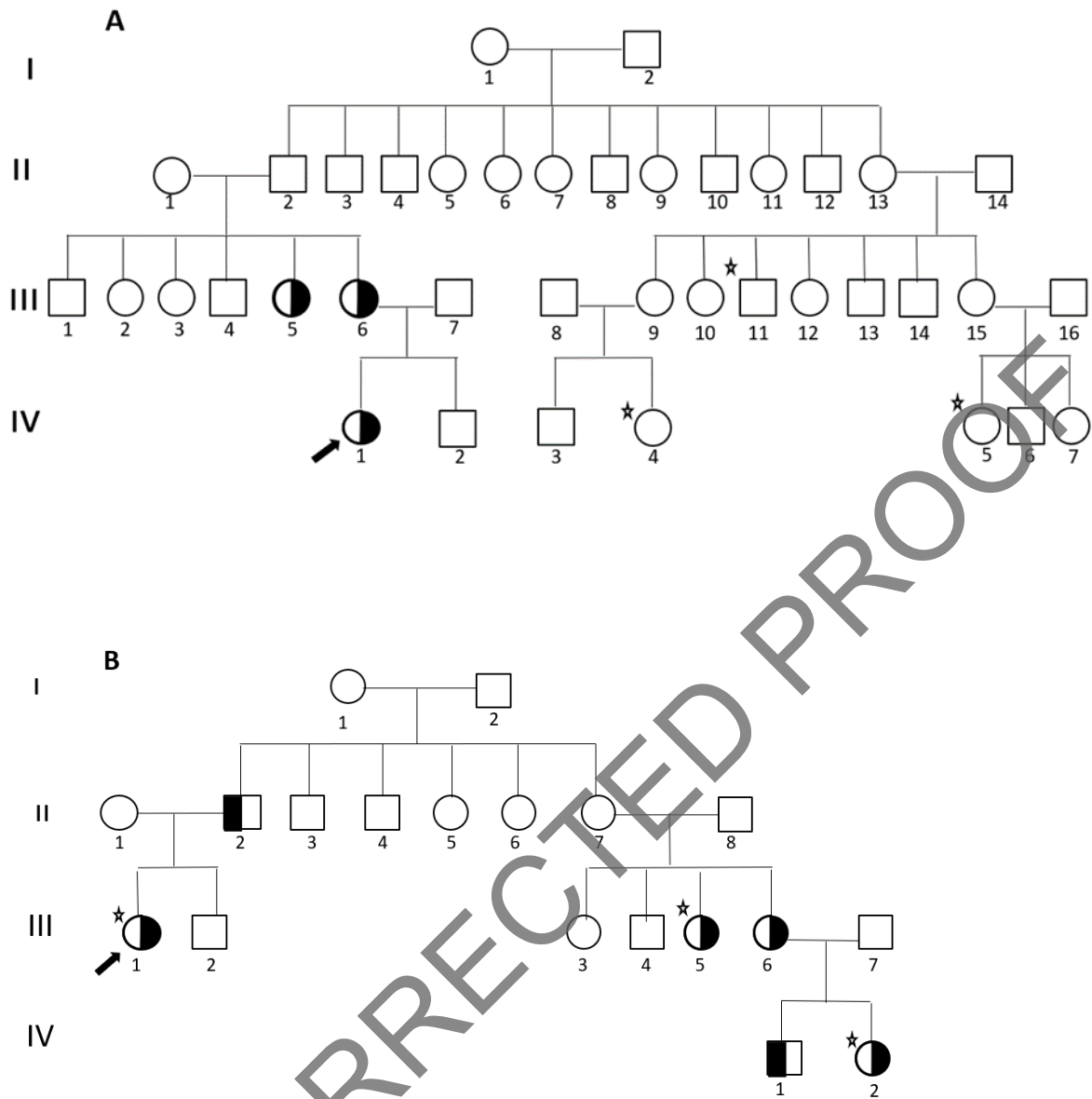


Fig.1 Pedigrees of the two families with PPNAD. Half-filled squares and circles represent heterozygous variant carriers. Individuals who were reported to have Cushing syndrome and underwent an adrenalectomy are indicated with a star. (A) Case 1 is subject IV.1 (c.440+5 G>A). Genetic analyses were made in subjects II.1, III.5, III.6, and IV.1. (B) Case 2 is subject III.1 (c.349G>T) and Case 3 is subject IV.2 (c.349G>T). Genetic analyses were made in subjects II.1, II.2, III.1, III.2, III.5, III.6, III.7, IV.1, and IV.2.

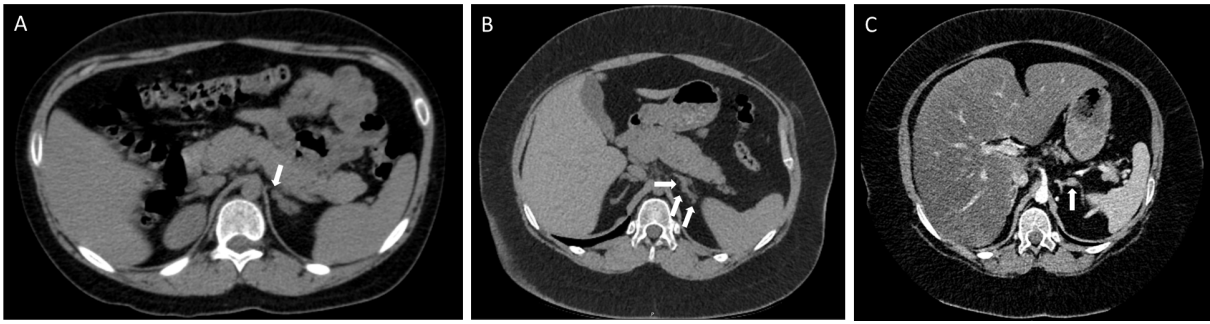


Fig 2. Adrenal CT images showing numerous adrenal nodules of varying sizes: (A) Case 1, (B) Case 2, and (C) Case 3

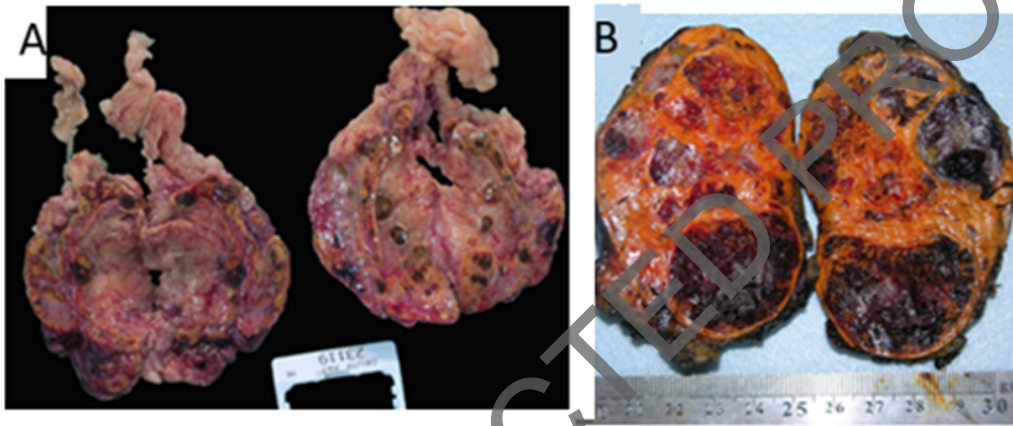


Fig 3. Gross view of a resected adrenal glands showing nodular changes. (A) Case 1, (B) Case 2. Multiple tan-brown nodules [(A) micronodules, (B) macro and micronodules] were seen in the cortex

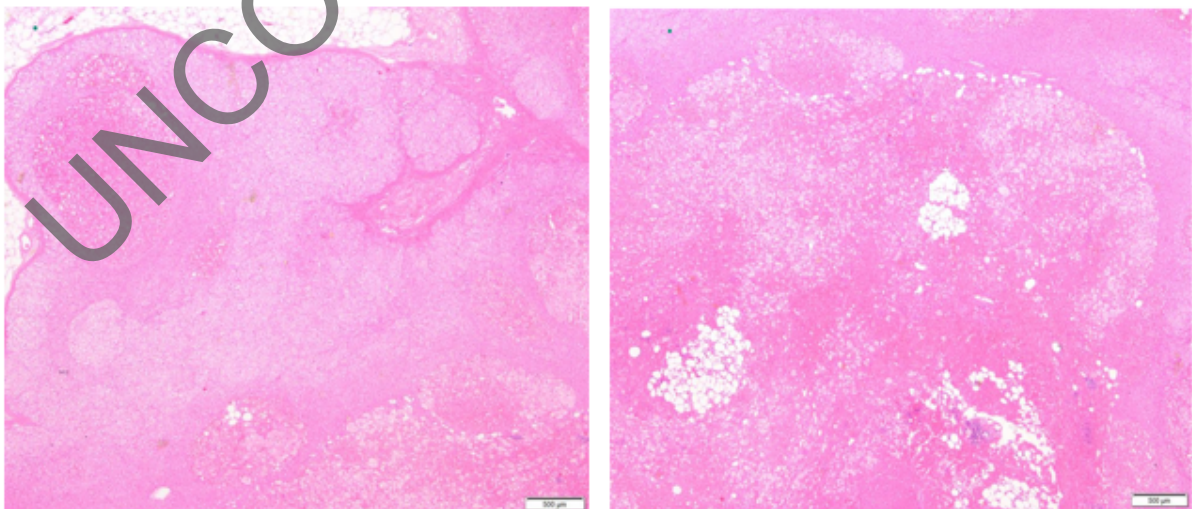


Fig 4 . Histopathological images of the adrenal of the case 2, nodules composed of clear and compact cells with variable lipid. No mitotic figures or atypical cells were present.