

Successful Management of Severe Hypercalcemia with Zoledronic Acid: A Report of Two Pediatric Cases

© Fatih Kilci¹, © Jeremy Huw Jones², © Filiz Mine Çizmecioglu-Jones¹

¹Kocaeli University Faculty of Medicine, Department of Pediatrics, Division of Pediatric Endocrinology, Kocaeli, Turkey

²Kocaeli University, Department of Academic Writing, Kocaeli, Turkey

What is already known on this topic?

Vitamin D intoxication and malignancies should be considered in the differential diagnosis of children presenting with hypercalcemia. Treatment of pediatric hypercalcemia with conventional bisphosphonates, such as pamidronate, can take many treatment cycles. There is a paucity of published evidence concerning the use of Zoledronic acid (ZA) in the treatment of pediatric severe hypercalcemia.

What this study adds?

ZA was an effective treatment in cases of severe hypercalcemia in children, due to two different etiologies, vitamin D intoxication and malignancy-associated hypercalcemia. Only one dose of ZA was sufficient to achieve normocalcemia within 48 hours in both cases. Patients should be followed closely after ZA infusion due to the risk of subsequent hypocalcemia.

Abstract

Severe hypercalcemia associated with vitamin D intoxication or malignancy in children is a rare and life-threatening condition. There is little published experience with Zoledronic acid (ZA) in the treatment of pediatric severe hypercalcemia. Here, we present two pediatric cases of severe hypercalcemia, one due to vitamin D intoxication and the second to malignancy, in which ZA was used as the first-line bisphosphonate in the treatment. While both cases responded well to a single dose of ZA, the second case experienced hypocalcemia requiring calcium treatment after ZA infusion. Our report shows that ZA may be an effective option in the treatment of severe pediatric hypercalcemia, although patients should be followed closely after infusion due to the risk of hypocalcemia. We provide additional published evidence for the effectiveness of ZA in correcting severe pediatric hypercalcemia and hope this will encourage future studies with larger numbers of patients.

Keywords: Hypercalcemia of malignancy, hypocalcemia, pamidronate, vitamin D intoxication, zoledronic acid

Introduction

Hypercalcemia in children is a rare condition that may present with a variety of signs and symptoms. Vitamin D intoxication and malignancy are among the known etiologies (1).

Although there is no formal classification to define the severity of hypercalcemia, serum calcium values greater than 14 mg/dL are considered severe hypercalcemia and

require urgent treatment (1). Bisphosphonates are effective in the treatment of hypercalcemia, and pamidronate is the most widely used bisphosphonate in children (2). However, data on the use of Zoledronic acid (ZA) in childhood are limited.

Herein, we present our experience with ZA as a first line treatment in two pediatric cases of severe hypercalcemia, the first secondary to vitamin D intoxication and the second case associated with malignancy.



Address for Correspondence: Fatih Kilci MD, Kocaeli University Faculty of Medicine, Department of Pediatrics, Division of Pediatric Endocrinology, Kocaeli, Turkey
Phone: +90 262 303 7500 **E-mail:** fatihkilci@gmail.com **ORCID:** orcid.org/0000-0003-4040-7908

Conflict of interest: None declared.

Received: 05.09.2022

Accepted: 03.10.2022



©Copyright 2024 by Turkish Society for Pediatric Endocrinology and Diabetes / The Journal of Clinical Research in Pediatric Endocrinology published by Galenos Publishing House. Licensed under a Creative Commons Attribution-NonCommercial-NoDerivatives 4.0 (CC BY-NC-ND) International License.

Case Reports

Case 1

A 22-month-old girl with known diagnoses of hydrocephalus and epilepsy was admitted to the emergency department with complaints of loss of appetite, constipation and polyuria. On examination, she was dehydrated and had hypotonicity. Vital signs were within normal limits. When the parents were questioned, it was learned that the girl had received a vitamin D supplement (cholecalciferol) with a dose of 300,000 IU daily for 20 days.

Initial laboratory investigations revealed severe hypercalcemia with an albumin-corrected serum calcium level of 17.8 mg/dL (normal: 8.8-10.6), ionized calcium level of 2.1 mmol/L (normal: 1.15-1.29), phosphorus level of 3.4 mg/dL (normal: 3.8-6.5), alkaline phosphatase level of 124 U/L (normal: 55-377), and creatinine level of 0.6 mg/dL (normal: 0.5-0.9). Complete blood count, other biochemical markers, and electrolytes were normal. Her serum intact-parathyroid hormone (PTH) level was 18 pg/mL (normal: 12-88), 25-hydroxyvitamin D level was 160 ng/mL (normal: 20-100), and 1,25-dihydroxy vitamin D level was 44.7 pg/mL (normal: 28-81). Spot urine analysis revealed a calcium/creatinine ratio of 1.1 (normal: <0.2) (Table 1). Renal ultrasonography showed increased bilateral medullar echogenicity, suggestive of nephrocalcinosis.

Then, intravenous (IV) fluids containing normal saline and dextrose at a dose of 150 mL/kg/day were started for the treatment of severe hypercalcemia due to vitamin D intoxication. IV furosemide with a dose of 2 mg/kg and methylprednisolone with a dose of 1 mg/kg were also administered for three days. ZA at a dose of 0.0125 mg/kg was administered IV, since a sufficient decrease in serum calcium values had not been achieved at that point. After 24 hours of ZA infusion, the calcium value decreased to 11.3 mg/dL from 14.2 mg/dL. There were no serious side effects or need for calcium supplementation after the ZA

infusion. The patient was discharged when the calcium value was 10.1 mg/dL, five days after the ZA infusion (Figure 1). While serum 25-hydroxyvitamin D values remained high or at the upper limit of normal for three months (Figure 2), calcium values 1 week, 1 month, 3 months and 1 year after discharge were within normal limits at 9.4 mg/dL, 9.6 mg/dL, 8.9 and 9.3 mg/dL, respectively.

Case 2

A previously healthy, 3-year-old boy presented with a 1-week history of difficulty in walking. On physical examination, he was mildly dehydrated and his vital signs were within normal range. His lower limbs were painful, but there was no sign of inflammation. Laboratory investigations revealed hypercalcemia, with an albumin-corrected serum calcium level of 13 mg/dL, ionized calcium level of 1.5 mmol/L, phosphorus level of 5.6 mg/dL, alkaline phosphatase level of 149 U/L, and creatinine level of 0.3 mg/dL. The rest of the biochemical markers, and electrolytes were normal. Complete blood count was also normal. His serum PTH

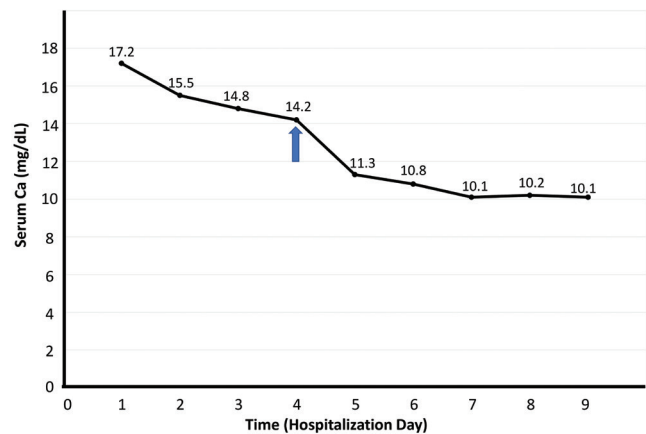


Figure 1. Serum calcium levels of Case 1 during hospitalization and response to Zoledronic acid. Zoledronic acid infusion is highlighted with a blue up-arrow

Ca: calcium

Table 1. Laboratory data of patients on admission

Parameter	Case 1	Case 2	Normal
Albumin-corrected serum calcium (mg/dL)	17.8	13	8.8-10.6
Ionized calcium (mmol/L)	2.1	1.5	1.15-1.29
Serum albumin (g/L)	43.3	44.6	35-52
Serum phosphorus (mg/dL)	3.4	5.6	3.8-6.5
Serum alkaline phosphatase (U/L)	124	149	55-377
Serum creatinine (mg/dL)	0.6	0.3	0.5-0.9
Serum intact-parathyroid hormone (pg/mL)	18	< 1.2	12-88
Serum 25-hydroxyvitamin D (ng/mL)	160	17.2	20-100
Serum 1,25-dihydroxy vitamin D (pg/mL)	44.7	16.5	28-81
Spot urine calcium/creatinine ratio (mg/mg)	1.1	1.1	< 0.2

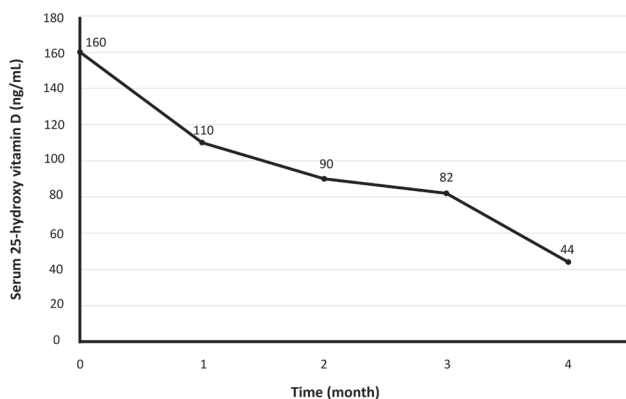


Figure 2. Time course of serum 25-hydroxyvitamin D levels of Case 1 after Zoledronic acid treatment

level was low at < 1.2 pg/mL, 25-hydroxyvitamin D level was low at 17.2 ng/mL, and 1,25-dihydroxyvitamin D level was in the lower limit of normal at 16.5 pg/mL. Spot urine analysis revealed a calcium/creatinine ratio of 1.1 (Table 1). Serum PTH-related peptide (PTHrP) could not be performed. Radiologic examinations of bones with X-rays and scintigraphy did not reveal any lytic lesions. Abdominal and renal ultrasound results were normal. Peripheral blood smears revealed blasts suggesting malignancy. Therefore, hematology was consulted. While further hematological investigations continued, normal saline and dextrose at a dose of 150 mL/kg/day were started to correct the hypercalcemia. Then, IV furosemide at a dose of 2 mg/kg/day was added. Despite fluid and furosemide, serum calcium increased to 15.2 mg/dL. Subsequently, ZA was administered with a dose of 0.0125 mg/kg. Serum calcium levels progressively decreased and normalized within 48 hours after the ZA infusion. Bone marrow examination and flow cytometry results were consistent with the diagnosis of acute lymphoblastic leukemia (ALL). Therefore, induction chemotherapy (vincristine, prednisolone, asparaginase and daunorubicin) was started. Three days after the ZA infusion serum calcium was 7.7 mg/dL and so calcium and vitamin D supplementations were provided (Figure 3). The patient is currently on his fourth month of chemotherapy treatment and there has been no recurrence of hypercalcemia.

Discussion

This case series describes two pediatric cases of severe hypercalcemia, one secondary to vitamin D intoxication and the other associated with malignancy, in which serum calcium levels were normalized shortly after ZA administration.

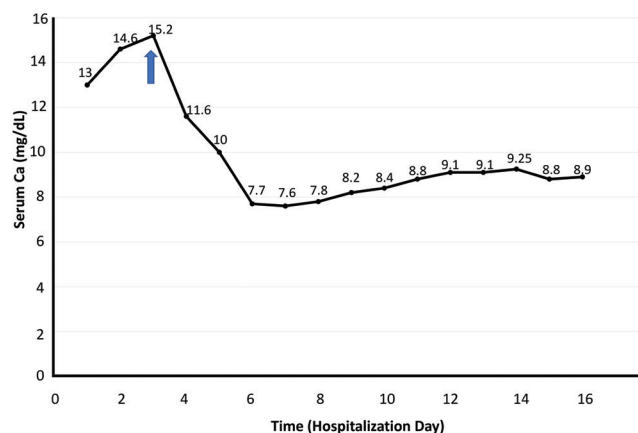


Figure 3. Serum calcium levels of Case 2 during hospitalization and response to Zoledronic acid. Zoledronic acid infusion is highlighted with a blue up-arrow

Causes of hypercalcemia in children can be classified as PTH-dependent or PTH-independent, based on serum PTH levels. In the presence of low PTH levels during severe hypercalcemia, vitamin D intoxication and malignancies are among the diagnoses that should be considered (1).

Administration of high doses of vitamin D due to incorrect prescription of vitamin D, formulation errors in drugs or unconscious use of vitamin D may lead to vitamin D intoxication and hypercalcemia. In intoxication caused by 25-hydroxyvitamin D, serum 25-hydroxyvitamin D levels are high, while 1,25-dihydroxyvitamin D levels are usually normal. This suggests that 1,25-dihydroxyvitamin D is not responsible for the development of hypercalcemia. 25-hydroxyvitamin D competes with calcitriol, binds to the vitamin D receptor and exerts biological effects resulting in hypercalcemia (3).

Hypercalcemia of malignancy (HCM) is extremely rare in the pediatric cancer population. The underlying mechanisms of HCM are secretion of PTHrP, local calcium release from osteolytic metastatic tissue, unregulated, extrarenal production of 1,25-dihydroxyvitamin D, and, rarely, ectopic PTH secretion (1). Although our patient did not have PTHrP measured, the low PTH and 1,25-dihydroxyvitamin D levels, as well as the absence of lytic lesions in radiological examinations, suggested the cause of HCM was most likely due to PTHrP secretion.

The standard approach for the management of hypercalcemia includes establishing the underlying diagnosis, discontinuing medications that may cause hypercalcemia, IV fluids, and antiresorptive therapy. Bisphosphonates are effective in the treatment of severe hypercalcemia, acting by reducing osteoclastic activity. Although there are studies showing

that pamidronate is effective and safe in the treatment of hypercalcemia due to both vitamin D intoxication and malignancy in childhood (4,5), definitive studies on the use of ZA in childhood hypercalcemia are lacking.

ZA has been shown to be superior to pamidronate in the treatment of HCM in adults. ZA normalized serum calcium levels earlier than pamidronate, while patients treated with pamidronate experienced an earlier recurrence of hypercalcemia than those treated with ZA (6). In a study evaluating the short-term safety of ZA in 81 young patients with various bone disorders, it was stated that acute side effects related to ZA infusion are common, occurring mainly after the first ZA infusion in bisphosphonate-naive patients, and are easily managed (7). Hypocalcemia is one of the side effects of ZA. It has been noted that low vitamin D level is a strong risk factor for hypocalcemia, and it has been suggested that the vitamin D level should be > 30 mg/dL before ZA infusion (8).

There are a few cases in the pediatric literature reporting that ZA is successful in the treatment of severe hypercalcemia due to both vitamin D intoxication and malignancy. Nimesh et al. (9) reported that they achieved normocalcemia with ZA in an infant with severe hypercalcemia due to vitamin D intoxication. Our case with vitamin D intoxication was first treated with fluid, furosemide, and methylprednisolone without good effect. However, normocalcemia was achieved within 48 hours after a single dose of ZA given because the calcium level continued to increase. Although serum calcium values remained within normal limits at one-year follow-up, late morbidities may develop due to the long half-life of 25-hydroxyvitamin D in serum and its accumulation in adipose tissues (3). It was noted that despite 19 repeated cycles of pamidronate in an infant who experienced severe hypercalcemia secondary to vitamin D intoxication, hypercalcemia could not be improved, and alendronate treatment was required for six weeks afterwards (10). Therefore, it should be kept in mind that the treatment and follow-up period may be long in intoxications caused by 25-hydroxyvitamin D. The persistence of hypervitaminosis for three months in the presented case may support the use of ZA in this situation. In addition, the rapid action, the lack of need for several repeated doses and shorter hospitalization time, unlike pamidronate, may further support the superiority of ZA to pamidronate in these cases.

In four children with ALL, published in four separate articles, who experienced HCM, it was reported that after a single dose of ZA, hypercalcemia resolved within 24-48 hours, and calcium replacement was required due to hypocalcemia (11,12,13,14). Similar to these reports, in the presented

case with HCM, serum calcium returned to normal limits within 48 hours after a single dose of ZA and calcium replacement was required due to hypocalcemia. The low 25-hydroxyvitamin D level of our case before ZA infusion may have contributed to hypocalcemia. We also believe that induction chemotherapy containing prednisolone may also predispose to hypocalcemia. Therefore, after ZA infusion, patients should be followed closely due to this risk of hypocalcemia.

A case of pediatric HCM unresponsive to pamidronate but successfully treated with ZA has also recently been published (15). In this report, three repeated doses of pamidronate were tried as the first-choice bisphosphonate, but since no response was obtained, a single dose of ZA was then administered. Hypercalcemia resolved 24 hours after the ZA administration and no further ZA doses were required. The authors indicated that ZA should be considered as a first line of treatment when bisphosphonates are required in the treatment of HCM.

Conclusion

Our experience in cases of severe hypercalcemia due to two different etiologies showed that ZA was effective in the treatment of severe hypercalcemia in childhood. Although it is not possible to report that ZA should be the first choice of bisphosphonate in childhood on the basis of only two cases, we hope that we have provided some evidence to encourage others to try ZA in pediatric cases, especially if recalcitrant to pamidronate therapy. We believe that as the evidence builds, the use of ZA in pediatric cases with severe hypercalcemia, may become more widespread, if it proves to be as effective as we have found.

Ethics

Informed Consent: Written informed consent was obtained from the parents on behalf of the children for treatment protocol, and publication of the case report.

Authorship Contributions

Surgical and Medical Practices: Fatih Kilci, Filiz Mine Çizmecioglu-Jones, Concept: Fatih Kilci, Jeremy Huw Jones, Filiz Mine Çizmecioglu-Jones, Design: Fatih Kilci, Jeremy Huw Jones, Filiz Mine Çizmecioglu-Jones, Data Collection or Processing: Fatih Kilci, Jeremy Huw Jones, Filiz Mine Çizmecioglu-Jones, Analysis or Interpretation: Fatih Kilci, Jeremy Huw Jones, Filiz Mine Çizmecioglu-Jones, Literature Search: Fatih Kilci, Jeremy Huw Jones, Filiz Mine Çizmecioglu-Jones, Writing: Fatih Kilci, Jeremy Huw Jones, Filiz Mine Çizmecioglu-Jones.

Financial Disclosure: The authors declared that this study received no financial support.

References

1. Stokes VJ, Nielsen MF, Hannan FM, Thakker RV. Hypercalcemic Disorders in Children. *J Bone Miner Res* 2017;32:2157-2170. Epub 2017 Nov 2
2. Davies JH, Shaw NJ. Investigation and management of hypercalcaemia in children. *Arch Dis Child* 2012;97:533-558. Epub 2012 Mar 23
3. Jones G. Pharmacokinetics of vitamin D toxicity. *Am J Clin Nutr* 2008;88:582-586.
4. Demir K, Döneray H, Kara C, Atay Z, Çetinkaya S, Çayır A, Anık A, Eren E, Uçaktürk A, Can Yılmaz G, Törel Ergür A, Kendirci M, Ayca Z, Bereket A, Aydın M, Orbak Z, Özkan B. Comparison of Treatment Regimens in Management of Severe Hypercalcemia Due to Vitamin D Intoxication in Children. *J Clin Res Pediatr Endocrinol* 2019;11:140-148. Epub 2018 Nov 5
5. Kerdudo C, Aerts I, Fattet S, Chevret L, Pacquement H, Doz F, Michon J, Garabedian M, Orbach D. Hypercalcemia and childhood cancer: a 7-year experience. *J Pediatr Hematol Oncol* 2005;27:23-27.
6. Major P, Lortholary A, Hon J, Abdi E, Mills G, Menssen HD, Yunus F, Bell R, Body J, Quebe-Fehling E, Seaman J. Zoledronic acid is superior to pamidronate in the treatment of hypercalcemia of malignancy: a pooled analysis of two randomized, controlled clinical trials. *J Clin Oncol* 2001;19:558-567.
7. George S, Weber DR, Kaplan P, Hummel K, Monk HM, Levine MA. Short-Term Safety of Zoledronic Acid in Young Patients With Bone Disorders: An Extensive Institutional Experience. *J Clin Endocrinol Metab* 2015;100:4163-4171. Epub 2015 Aug 26
8. Bowden SA, Mahan JD. Zoledronic acid in pediatric metabolic bone disorders. *Transl Pediatr* 2017;6:256-268.
9. Nimesh M, Singh P, Jhamb U, Dubey AP. An Unsuspected Pharmacological Vitamin D Toxicity in a Child and its Brief Review of Literature. *Toxicol Int* 2015;22:167-169.
10. Hatun S, Cizmecioglu F. Use of alendronate in the treatment of vitamin D intoxication in infants. *Turk J Pediatr* 2005;47:373-375.
11. Park HJ, Choi EJ, Kim JK. A successful treatment of hypercalcemia with zoledronic acid in a 15-year-old boy with acute lymphoblastic leukemia. *Ann Pediatr Endocrinol Metab* 2016;21:99-104. Epub 2016 Jun 30
12. Kolyva S, Efrhymiadou A, Gkenti D, Karana-Ginopoulou A, Varvarigou A. Hypercalcemia and osteolytic lesions as presenting symptoms of acute lymphoblastic leukemia in childhood. The use of zoledronic acid and review of the literature. *J Pediatr Endocrinol Metab* 2014;27:349-354.
13. Bota M, Popa G, Neaga A, Gocan H, Blag CL. Acute Lymphoblastic Leukemia with Malignant Hypercalcemia: A Case Report. *Am J Case Rep* 2019;20:402-405.
14. Martins AL, Moniz M, Nunes PS, Abadeso C, Loureiro HC, Duarte X, Almeida HI. Severe hypercalcemia as a form of acute lymphoblastic leukemia presentation in children. *Rev Bras Ter Intensiva* 2015;27:402-405.
15. Colak U, Mutlu GY, Sozmen BO, Yucel EB, Kayserili H, Hatun S. Zoledronate-responsive calcitriol-mediated hypercalcemia in a 5-year-old case with squamous cell carcinoma on the background of xeroderma pigmentosum. *J Pediatr Endocrinol Metab* 2019;32:1403-1406.